EDD RETRIEVAL RECEIPT

Order: 413948
For: EDD
Copied: 06/09/2016
Shipped: 06/09/2016
Deliver To: Kelly E. Grimes
Patron E-Mail: kg2648@columbia.edu
Oth Patron Info: -kg2648-Dept of Orthopaedic Surgery-
Def PickUp Loc: HS-Columbia Health Sciences Library
Delivery Meth: WEB

Item BarCode: HR02080354
Item Title: Journal of bone and joint surgery.
Item Author:
Item Call Number: Serial J
Item Vol/Part: v.65:no.4-6 (19

Article Title: Curve progression in idiopathic scoliosis
Article Author: Weinstein SL
Art Vol/Part: 65-4, 1983
Beg Page: 447 End Page: 455 Total Pages: 9
Other Info:
Notes: - 3945569- 2016.06.08 17:43:17

TOTAL COUNT: 2

Curve Progression in Idiopathic Scoliosis

BY STUART L. WEINSTEIN, M.D.*, AND I. V. PONSETI, M.D.*, IOWA CITY, IOWA

From the Department of Orthopaedics, University of Iowa Hospitals, Iowa City

ABSTRACT: **One hundred and thirty-three curves in 102 patients who were followed for an average of 40.5 years were evaluated to quantitate curve progression after skeletal maturity and for prognostic factors leading to curve progression. Sixty-eight per cent of the curves progressed after skeletal maturity. In general, curves that were less than 30 degrees at skeletal maturity tended not to progress regardless of curve pattern. In thoracic curves the Cobb angle, apical vertebral rotation, and the Mehta angle were important prognostic factors. In lumbar curves the degree of apical vertebral rotation, the Cobb angle, the direction of the curve, and the relationship of the fifth lumbar vertebra to the intercrest line were of prognostic value. Translatory shifts played an important role in curve progression. Curves that measured between 50 and 75 degrees at skeletal maturity, particularly thoracic curves, progressed the most.**

For optimum treatment of patients with idiopathic scoliosis, the surgeon should have an extensive understanding of the natural history of the disease. There have been few studies with long-term follow-up of untreated patients with idiopathic scoliosis[4,9,17,19,32]. Originally it was thought that once skeletal maturity was reached, there would be no tendency to progression of a curve[3,28]. However, two previous reports from our institution have demonstrated that progression of the curve will indeed occur after skeletal maturity is reached[4,32]. It is the purpose of this paper to further evaluate and quantify progression of curves in patients with untreated adolescent idiopathic scoliosis, and to identify some of the prognostic factors that tend to make curves worse after maturity.

Materials and Methods

We were able to locate 102 patients who were seen at the University of Iowa between 1932 and 1948, who then had roentgenograms made at the time of skeletal maturity. Skeletal maturity was diagnosed by Risser's method as either grade IV (iliac apophysis completely ossified) or grade V (iliac apophysis fused to the ilium)[27,31,34]. Most patients had additional roentgenograms available in 1968 and each patient had a standing roentgenogram made at current follow-up. The study was restricted to a consideration of primary curves only.

* Department of Orthopaedics, University of Iowa Hospitals, Iowa City, Iowa 52242.

Thirty-one patients had a thoracic curve, thirty patients had a lumbar curve, ten patients had a thoracolumbar curve, and thirty-one patients had combined (double primary) curves. The thoracic and lumbar components of combined (double primary) curves were considered separately. Thus, information was available on 133 curves in 102 patients. The patients were evaluated as a group and by curve pattern[25]. Each of the following seven factors was evaluated for its prognostic value. (1) All roentgenograms (those made at maturity and at final follow-up, and any intervening roentgenograms) were first evaluated for the degree of curvature as measured by the Cobb method[3]. (2) The per cent rotation was measured at the apical vertebra by expressing the amount of displacement of the pedicle on the convex side as a percentage of the entire width of the vertebral body[18]. (3) The Mehta (rib-vertebra) angle[15] (in thoracic and thoracolumbar curves, and in the thoracic component of combined curves) then was recorded. (4) We also evaluated the relationship between the body of the fifth lumbar vertebra and the line joining the iliac crests[14]. The fifth lumbar vertebra was said to be well seated if the intercrest line passed through the disc space between the fourth and fifth lumbar vertebrae or lay above that level. (5) So-called translatory shifts between vertebral bodies were recorded, as were (6) lumbarization of the first sacral vertebra and (7) sacralization of the fifth lumbar vertebra. Lateral roentgenograms often were not available and thus kyphosis, lordosis, and sacral inclination could not be studied.

The study comprised sixteen men and eighty-six women. The average age at follow-up was 53.8 years (range, forty-one to sixty-five years). The patients were followed for an average of 40.5 years (range, thirty-one to fifty-three years).

Results

The average curve at skeletal maturity measured 50.3 degrees (range, 15 to 135 degrees) for the entire group. At final follow-up the average curve measured 63.7 degrees (range, 15 to 148 degrees), for an average increase of 13.4 degrees (range, zero to 48 degrees).

During the follow-up period, ninety (68 per cent) of the 133 curves progressed more than 5 degrees and forty-three (32 per cent) progressed 5 degrees or less (the so-called non-progressive curves). The non-progressive curves included nine of thirty-one thoracic, seventeen of thirty lumbar, and three of ten thoracolumbar curves; seven of thirty-one thoracic components of combined

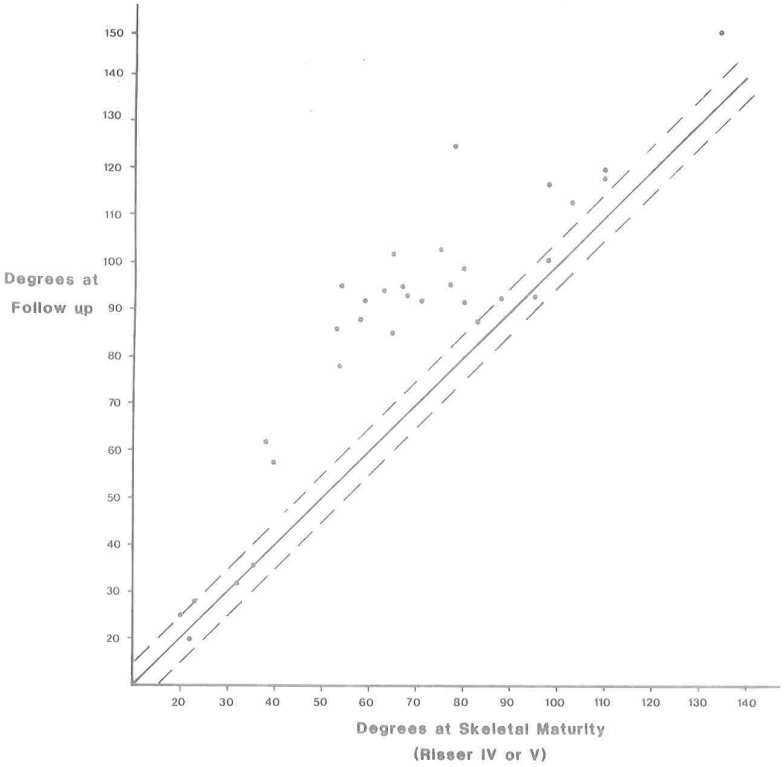

FIG. 1

Thoracic curve progression for each patient. The solid line represents no change in the curve. The parallel broken lines indicate ±5 degrees.

curves; and seven of thirty-one lumbar components of combined curves.

Thoracic Curves

Thirty-one patients (twenty-one women and ten men) had a thoracic curve (Table I). The average curve at maturity measured 68 degrees (range, 20 to 135 degrees) and at final follow-up it measured 85.1 degrees (range, 22 to 148 degrees), for an average increase of 17.1 degrees (Fig. 1). For the three thoracic curves that were less than

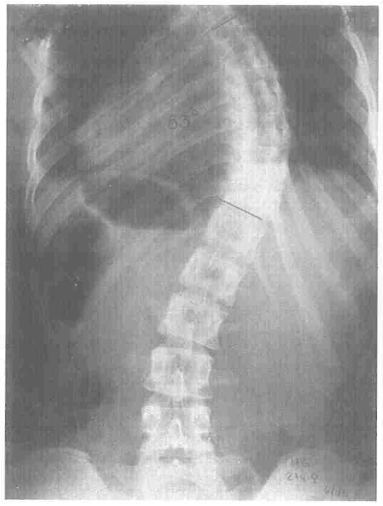

FIG. 2-A

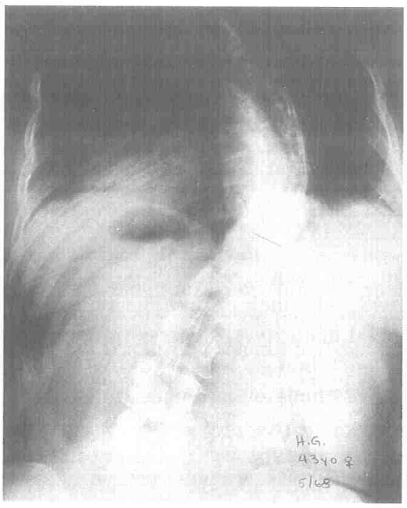

FIG. 2-B

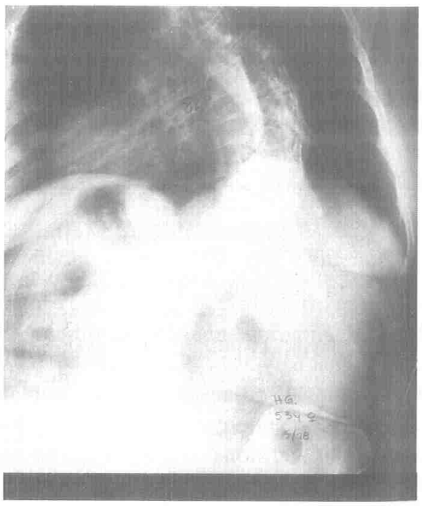

FIG. 2-C

Figs. 2-A, 2-B, and 2-C: Typical progression of a thoracic curve that was greater than 50 degrees at skeletal maturity.
Fig. 2-A: At the age of twenty-one years the thoracic curve measures 53 degrees, with apical vertebral rotation of 34 per cent and a 30-degree difference in the rib-vertebra angle.
Fig. 2-B: At the age of forty-three years the curve measures 67 degrees.
Fig. 2-C: At the age of fifty-three years the curve measures 86 degrees.

TABLE I

CURVE PROGRESSION (IN DEGREES)

	Thoracic Curves (31 Patients)		Lumbar Curves (30 Patients)		Thoracolumbar Curves (10 Patients)		Combined Curves (31 Patients)			
							Thoracic Component		Lumbar Component	
	Average	Range	Average	Range	Average	Range	Average	Range	Average	Range
< 30 degrees at skeletal maturity										
At skeletal maturity	21.7	20-23	24.7	15-28	20.5	18-23	28	28	21.5	20-29
At final follow-up	24.3	22-28	24.7	15-45	34.5	24-45	31	30-32	27.1	26-47
Progression	2.6	0-5	0	−3-21	14.0	6-22	3	2-4	5.6	0-18
30 to 50 degrees at skeletal maturity										
At skeletal maturity	36.3	32-38	39.3	30-47	38.5	30-47	43.7	32-48	40.4	33-48
At final follow-up	46.5	32-62	54.7	30-74	49.5	47-52	53.8	41-73	53.1	33-72
Progression	10.2	0-24	15.4	0-36	11	0-22	10.1	3-26	12.7	0-34
50 to 75 degrees at skeletal maturity										
At skeletal maturity	61.5	53-75	54.8	51-62	62	50-85	61.2	50-73	52.2	50-62
At final follow-up	90.9	78-103	73.3	61-78	84.3	54-108	79.5	54-108	75.3	50-100
Progression	29.4	20-41	18.5	7-26	22.3	4-48	18.3	0-36	23.1	0-42
75 to 100 degrees at skeletal maturity*										
At skeletal maturity	85.1	77-98					88.5	80-97	80.3	76-88
At final follow-up	97.7	92-117					99.5	90-109	95.7	88-103
Progression	12.6	2-19					11	10-12	15.4	10-18
> 100 degrees at skeletal maturity†										
At skeletal maturity	114.5	103-135								
At final follow-up	124.8	113-148								
Progression	10.3	8-13								

* For lumbar and thoracolumbar curves, this group includes all curves that measured more than 50 degrees at skeletal maturity.
† For combined curves, this group includes all curves that measured more than 75 degrees at skeletal maturity.

30 degrees at skeletal maturity there was virtually no progression (average, 2.6 degrees) over the follow-up period. For the twenty-eight curves that were greater than 30 degrees, the average curve at maturity measured 73 degrees and at final follow-up it measured 92 degrees, for an average progression of 19 degrees. The most marked progression was noted in the eleven curves that measured between 50 and 75 degrees at skeletal maturity; they progressed an average of 29.4 degrees over the follow-up period (Figs. 2-A, 2-B, and 2-C).

All of the thoracic curves that measured less than 30 degrees at maturity had less than 20 per cent rotation of the

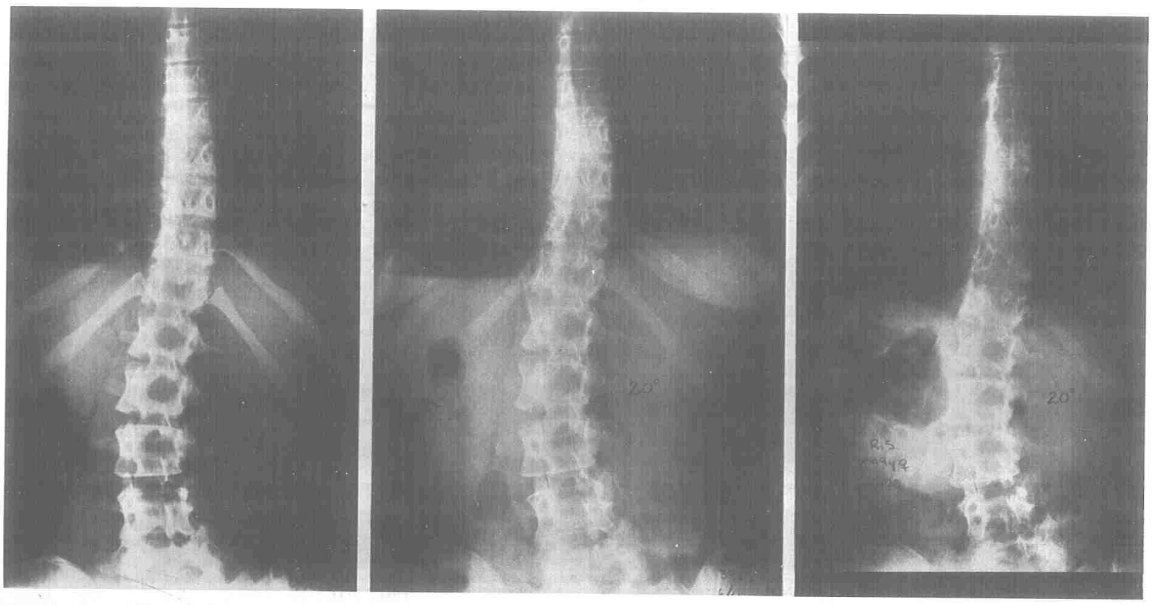

FIG. 3-A FIG. 3-B FIG. 3-C

Figs. 3-A, 3-B, and 3-C: Progression of a lumbar curve.
Fig. 3-A: At the age of seventeen the curve measures 17 degrees and apical vertebral rotation is 16 per cent.
Fig. 3-B: At the age of thirty-nine the curve measures 20 degrees and apical vertebral rotation is 18 per cent.
Fig. 3-C: At the age of forty-nine the curve measures 20 degrees and apical vertebral rotation is 18 per cent.

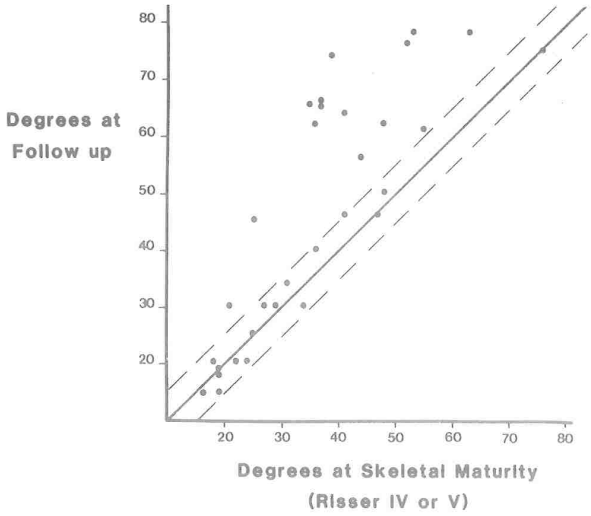

FIG. 4

Lumbar curve progression for each patient. The solid line represents no change in the curve. The parallel broken lines indicate ±5 degrees.

apical vertebra and all had a Mehta angle of less than 20 degrees. All twenty-four of the curves that measured more than 50 degrees at skeletal maturity had more than 30 per cent apical vertebral rotation. In addition, all of these curves had a Mehta angle of more than 20 degrees and most of them were between 30 and 60 degrees. As measured by a plumb line from the seventh cervical vertebra, the compensation in balance improved as compensatory curves developed.

Lumbar Curves

Thirty patients (twenty-seven women and three men) had a lumbar curve (Table I). The average curve at maturity was 35.1 degrees (range, 15 to 62 degrees) and at final follow-up it measured 44.7 degrees (range, 15 to 78 degrees), for an average progression of 9.6 degrees (Fig. 4). For the thirteen lumbar curves that measured less than 30 degrees at skeletal maturity, the average curve measured 24.7 degrees both at maturity and at final follow-up (Figs. 3-A, 3-B, and 3-C). Two curves in this group regressed somewhat. Only one lumbar curve that was less than 30 degrees at skeletal maturity (24 degrees) had significant progression, to 45 degrees. Two patients with curves of less than 30 degrees at skeletal maturity had apical vertebral rotation greater than 33 per cent. In one patient the fifth lumbar vertebra was completely sacralized and there was no progression. In the other patient the fifth lumbar vertebra was not well seated, significant progression occurred, and there was a 20 per cent translatory shift of the third lumbar vertebra on the fourth (Figs. 5-A and 5-B).

For the seventeen lumbar curves that were greater than 30 degrees, the average curve measured 42.9 degrees at skeletal maturity and 59.1 degrees at final follow-up, for an average progression of 16.2 degrees. The average curve progression for the eight right lumbar curves (22.3 de-

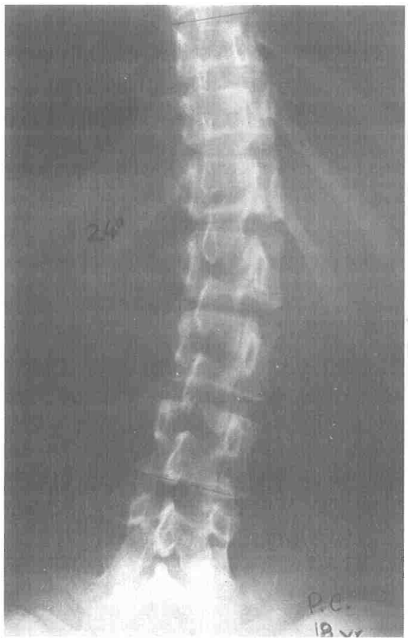

FIG. 5-A

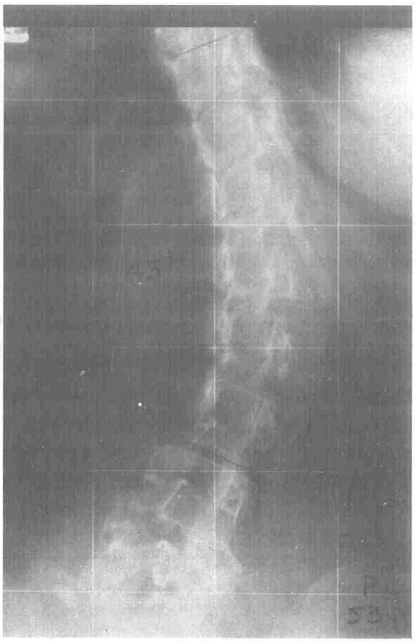

FIG. 5-B

Figs. 5-A and 5-B: Progression of a right lumbar curve.

Fig. 5-A: At the age of eighteen the right lumbar curve measures 24 degrees, the apical vertebral rotation is 33 per cent, and the fifth lumbar vertebra is high-riding in relation to the intercrest line.

Fig. 5-B: At the age of fifty-three years the curve measures 45 degrees, there has been increasing vertebral rotation to 41 degrees, and there is a translatory shift of the third lumbar vertebra on the fourth.

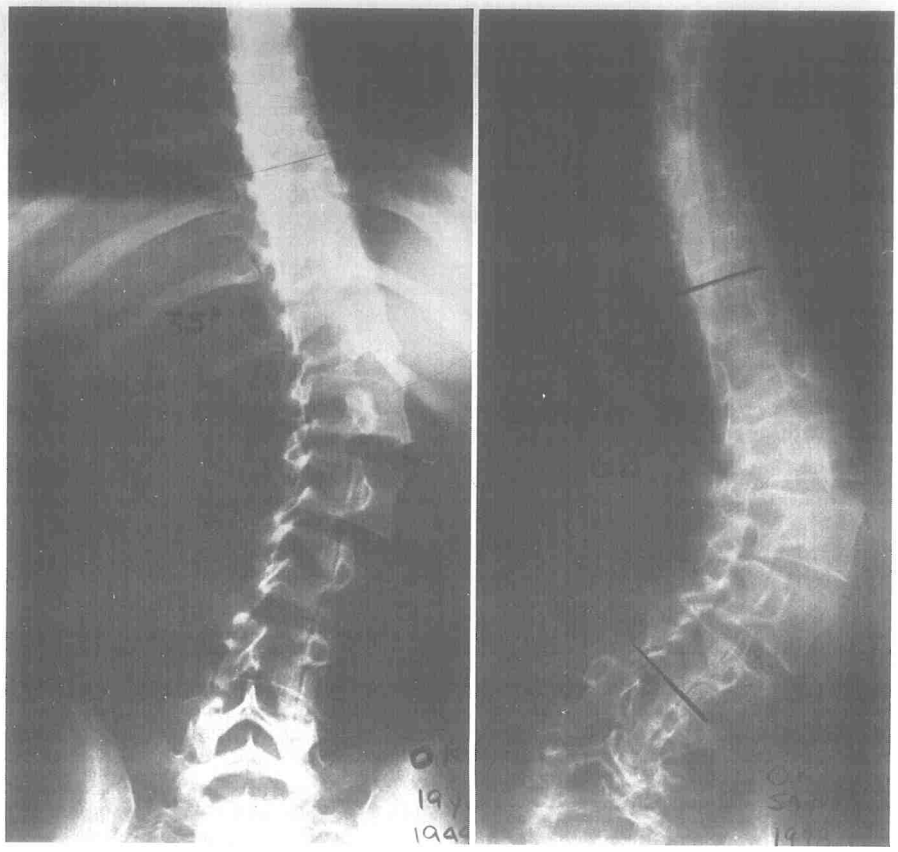

FIG. 6-A FIG. 6-B

Figs. 6-A and 6-B: Progression of a right lumbar curve.

Fig. 6-A: At the age of nineteen years the right lumbar curve measures 35 degrees. The first sacral vertebra is lumbarized and the apical vertebral rotation is 40 per cent.

Fig. 6-B: At the age of fifty-four the curve measures 62 degrees and the apical vertebral rotation has increased to 50 per cent. There is a translatory shift of the third lumbar vertebra on the fourth and lateral tilting of the fourth lumbar vertebra on the fifth toward the convexity of the curve.

grees) was twice as much as the average curve progression for the nine left lumbar curves (11.6 degrees) ($p < 0.01$). All seventeen of the curves had apical vertebral rotation of more than 33 per cent. Significant progression was seen in all but four of these curves (Fig. 4). In two of them the fifth lumbar vertebra was sacralized and in the other two it was well seated, with the intercrest line passing through the upper portion of the body of the fourth lumbar vertebra. These four curves were the only ones in the group measuring more than 30 degrees at skeletal maturity that did not have translatory shift at follow-up. In the remaining curves that were greater than 30 degrees, the translatory shifts were usually at the level of the third and fourth lumbar vertebrae but occasionally occurred at the level of the fourth and fifth lumbar vertebrae (Figs. 6-A and 6-B). Accompanying translatory shift was lateral tilting of the fourth lumbar vertebra on the fifth toward the convexity, particularly if the fifth lumbar vertebra was not well seated.

Thoracolumbar Curves

Ten patients (all women) had a thoracolumbar curve (Table I). The average curve at skeletal maturity measured 49 degrees (range, 18 to 85 degrees) and at final follow-up it measured 67.4 degrees (range, 24 to 108 degrees), for an

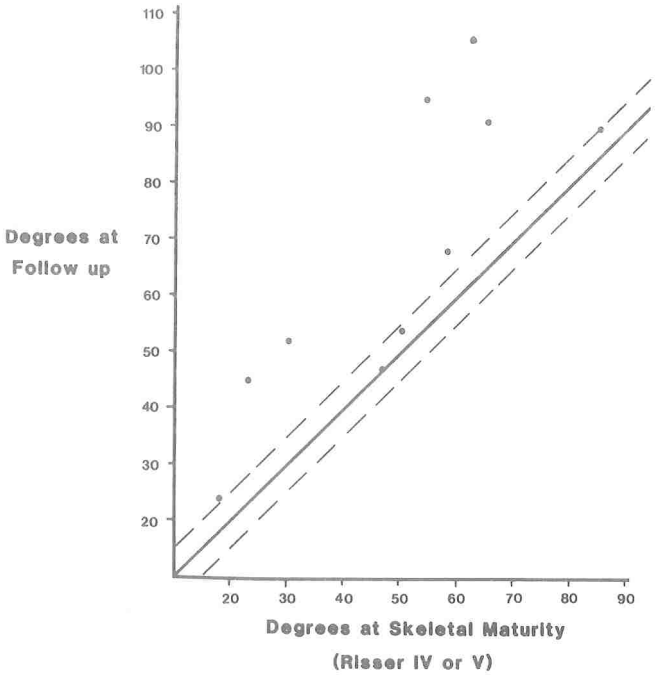

FIG. 7

Thoracolumbar curve progression for each patient. The solid line indicates no change in the curve. The parallel broken lines indicate ±5 degrees.

average increase of 18.4 degrees (Fig. 7). Only two curves measured less than 30 degrees at skeletal maturity; one progressed only 6 degrees while the other progressed 22 degrees and a translatory shift developed in the curve below. The eight curves that were 30 degrees or greater at skeletal maturity had significant apical vertebral rotation (range, 40 to 65 per cent) and the average curve, which measured 56 degrees at skeletal maturity, measured 75.6 degrees at final follow-up, for an average progression of 19.6 degrees. As in the thoracic group, the curves that measured between 50 and 75 degrees at skeletal maturity progressed the most, increasing an average of 22.3 degrees during the forty-year period. A translatory shift between two vertebrae was noted at the lower end of each of these curves. The per cent of vertebral rotation increased with increasing severity of the curve.

Combined (Double Primary) Curves

Thirty-one patients (twenty-eight women and three men) had combined (double primary) curves (Table I). The average of the thoracic curves was 52.9 degrees (range, 28 to 97 degrees) at skeletal maturity and 66.4 degrees (range, 30 to 109 degrees) at follow-up, for an average increase of 13.5 degrees. The average of the lumbar curves was 46.2 degrees (range, 20 to 88 degrees) at skeletal maturity and 60.4 degrees (range, 26 to 103 degrees) at final follow-up, for an average increase of 14.2 degrees over the forty years (Fig. 9).

For the two thoracic curves that were less than 30 degrees at skeletal maturity there was virtually no change (2 and 4 degrees) in curvature during the follow-up period. Only slightly greater progression occurred in the five lumbar components of the combined curves that measured less than 30 degrees at skeletal maturity. They had progressed an average of only 5.6 degrees at final follow-up.

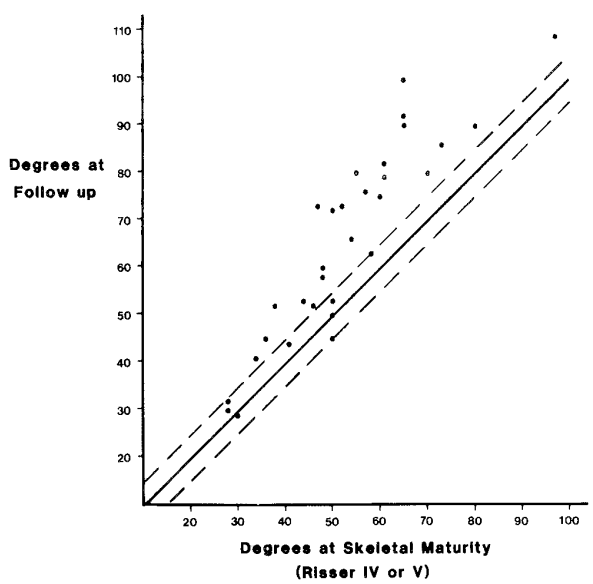

FIG. 8

Progression of the thoracic component of a combined curve for each patient. The solid line represents no change in the curve. The parallel broken lines indicate ±5 degrees.

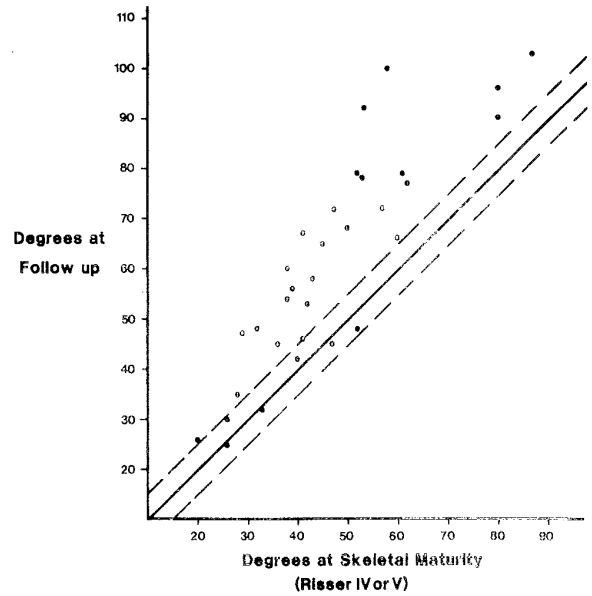

FIG. 9

Progression of the lumbar component of a combined curve for each patient. The solid line represents no change in the curve. The parallel broken lines indicate ±5 degrees.

For the twenty-nine thoracic components of combined curves that were greater than 30 degrees at skeletal maturity the average increase in curvature was 14.2 degrees, while the twenty-six lumbar components of combined curves that were greater than 30 degrees at skeletal maturity progressed an average of 15.5 degrees during the follow-up period. In both components the most marked progression occurred in curves measuring between 50 and 75 degrees at skeletal maturity (Figs. 8 through 10-C), and the lumbar component showed more progression than did the thoracic. The average progression was 23.1 degrees in the lumbar component and 18.3 degrees in the thoracic component.

In the combined (double primary) curves the thoracic and lumbar components measured within 10 degrees of each other both at skeletal maturity and at final follow-up in all but nine patients. At skeletal maturity the majority of thoracic components were larger than the lumbar components, as expressed by the ratio of the thoracic component to the lumbar component. At follow-up, however, these ratios tended to decrease, reflecting the selective greater progression in the lumbar components over the years (Fig. 11). The parameters of the Mehta angle, the per cent apical vertebral rotation, and the relationship of the fifth lumbar vertebra to the intercrest line did not correlate with curve progression in combined curves. The extreme degree of vertebral rotation seen in severe thoracolumbar and lumbar curves was not present in comparable components of combined curves. The Mehta angle in the thoracic components of combined curves was uniformly low. Translatory

FIG. 10-A FIG. 10-B FIG. 10-C

Figs. 10-A, 10-B, and 10-C: A combined curve.
Fig. 10-A: At the age of seventeen the right thoracic component measures 55 degrees and the left lumbar component measures 53 degrees.
Fig. 10-B: At the age of forty-six the right thoracic component measures 70 degrees and the left lumbar component measures 73 degrees.
Fig. 10-C: At the age of fifty-six the right thoracic component measures 80 degrees and the left lumbar component measures 90 degrees. Through the years there has been an increasing translatory shift at the junction of the two components, in addition to a similar shift at the junctions of the third and fourth and of the fourth and fifth lumbar vertebrae.

shifts were seen at the transition of the two components in curves that were greater than 50 degrees.

Discussion

Over the past twenty years information has been accumulating on the natural history of scoliosis[2,4,5,9,11,13,17,19,25,29,30,32,34]. Several recent studies have addressed the question of curve progression prior to skeletal maturity[2,13,29]. That curves progress after skeletal maturity was first definitely established by Collis and Ponseti[4] and by Duriez[5]. A later long-term follow-up by Weinstein et al. demonstrated that many curves continue to progress throughout adult life[32].

Scott and Piggott reported an eleven-year follow-up of thirty patients with an average age of twenty-eight years. In this short natural-history follow-up, 60 per cent of the curves progressed. Curves of more than 30 degrees with apical vertebral rotation greater than 25 per cent were twice as likely to progress[30].

In the present study, 68 per cent of the curves progressed after skeletal maturity. In general, curves that were less than 30 degrees at skeletal maturity tended not to progress. Exceptions to this rule occurred with a lumbar curve in which the fifth lumbar vertebra was not well seated and apical vertebral rotation was greater than 33 per cent. There was significant curve progression and translatory shift at the lower end of the curve. Only one patient, with severe osteoporosis, had collapse of one lumbar vertebral body and an increase in the spinal curvature.

In thoracic curves the Mehta angle, apical vertebral rotation, and the Cobb angle were important prognostic factors. The most marked progression in this series occurred in thoracic curves that measured between 50 and 75 degrees at skeletal maturity. These curves progressed almost 1 degree per year over the forty-year period. They all had apical vertebral rotation of more than 30 per cent

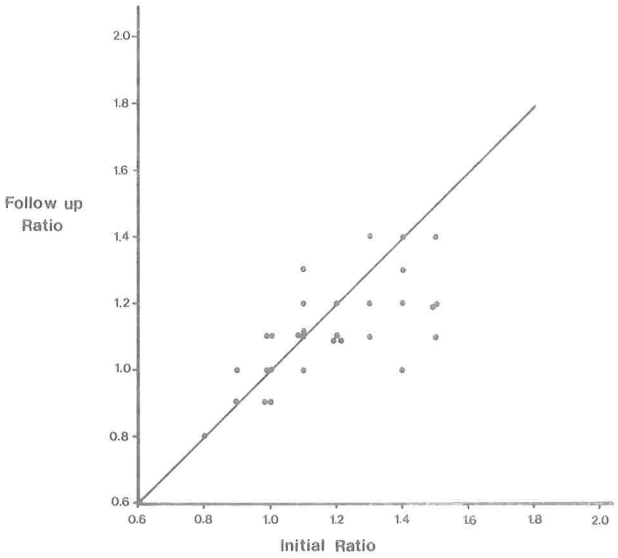

FIG. 11

The ratio of the thoracic component to the lumbar component in combined curves at skeletal maturity and at final follow-up.

and a Mehta angle of more than 30 degrees, with many being in the 30 to 60-degree range. The Mehta angle appears to be influenced by extreme degrees of vertebral rotation[23,24].

The importance of the rib cage to spinal stability has been demonstrated by Michelsson[16] and by Langenskiold and Michelsson[12] in a study in rabbits, in which resection of the costovertebral ligaments or the dorsal rib ends reliably produced scoliosis. Farkas indicated that intrasegmental movement of the vertebral body in scoliosis is caused by relaxation of the costovertebral joints[8]. Andriacchi et al. demonstrated that the rib cage markedly increases the axial stability of the spine[1].

In lumbar curves the degree of apical vertebral rotation, the Cobb angle, the direction of the curve, and the relationship of the fifth lumbar vertebra to the intercrest line were of prognostic value. The curves that measured more than 30 degrees at skeletal maturity progressed an average of 16.2 degrees over the forty-year period. Right lumbar curves, on the average, progressed twice as much as left lumbar curves. All lumbar curves that were greater than 30 degrees at skeletal maturity had apical vertebral rotation of more than 33 per cent. The four curves in this group that did not progress were those that had either a sacralized or a well seated fifth lumbar vertebra. The more marked progression of the right lumbar curves cannot be readily explained.

Farfan et al. demonstrated that annular tears are the result of torsional rather than compressive failure[6,7]. MacGibbon and Farfan demonstrated, in 554 patients, that a high intercrest line (that is, a well seated fifth lumbar vertebra) is an antitorsional device, thus reducing the risk of annular tears and disc degeneration, while a low intercrest line provided no antitorsional protection to the discs between the fourth and fifth lumbar vertebrae and the fifth lumbar and first sacral vertebrae[14]. When the fifth lumbar vertebra was not well seated and there was a high percentage of vertebral rotation, the curve tended to progress and significant translatory shifts occurred at the lower end of the curve, often accompanied by tilting of the fourth on the fifth lumbar vertebra toward the convexity of the curve. The roles of torsion and rotation were recently investigated by Perdriolle[23] and Perdriolle and Vidal[24] and were found to be prognostic factors in progression of thoracic curves.

The number of patients with thoracolumbar curves was too small for us to draw significant conclusions. However, this group had the most striking examples of a high percentage of apical vertebral rotation (40 to 65 per cent). This marked rotation, in combination with translatory shift at the lower end of the curve, led to significant progression.

In combined curves the most significant progression occurred in components that measured between 50 and 75 degrees at skeletal maturity, with lumbar components progressing to a slightly greater degree than thoracic components. The percentage of apical vertebral rotation, the Mehta angle, and the relationship of the fifth lumbar vertebra to the intercrest line did not correlate with curve progression. The extreme degrees of rotation seen in severe thoracolumbar and lumbar curves were not seen in combined curves, and usually the ribs remained level. With aging, translatory shifts were often seen at the transition between the two curves. In addition, the lumbar components tended to increase slightly more than the thoracic components, as evidenced by decreased ratios of the thoracic to the lumbar component.

There is increasing evidence of biochemical changes in the intervertebral disc in scoliosis[10,20-22,26,33]. Pedrini-Mille et al. recently found decreased amounts of proteoglycan aggregates as well as non-aggregated monomers in the convex portions of the end-plates in patients with scoliosis[22]. Pedrini et al. previously identified decreased proteoglycan and glycoprotein and increased collagen content in the nucleus pulposus of patients with idiopathic scoliosis[21]. Zaleske et al. confirmed the latter findings and demonstrated similar findings, but to a greater magnitude, in patients with meningomyelocele[33]. The changes of decreased glycosaminoglycan content and increased acid phosphatase, indicative of increased degradative enzyme activity, are similar to the changes seen in the hyaline cartilage of osteoarthritic joints[33].

Ghosh et al., in zonal analysis, found distribution differences with glycosaminoglycans in the annulus fibrosus of the scoliotic disc on the concave and convex sides[10]. Parsons et al. reported that the annulus of patients with adolescent scoliosis contained more Type-I collagen than normal and that the distribution of the Type-I and Type-II collagen was different in the scoliotic annuli compared with normal, with an increased proportion of Type-I collagen in the concave side of the annulus and a decreased proportion of Type-I collagen in the outer layer of the convex side[20].

It remains to be proved whether the biochemical alterations are primary or secondary. However, it appears that these alterations in proteoglycan distribution and proteoglycan:collagen ratios in the intervertebral disc unit and costotransverse articulation can alter the structural stability of the spine, subjecting it to biomechanical influences leading to curve progression.

In summary, in patients with adolescent idiopathic scoliosis whose curves measure less than 30 degrees at skeletal maturity, the curves tend not to progress regardless of curve pattern. Progression of curves that are greater than 30 degrees appears to be related to the amount of vertebral rotation. Thoracic curves between 50 and 75 degrees progress most rapidly, at approximately 0.75 to 1 degree per year. The progression of lumbar curves appears to be related to vertebral rotation, the direction of the curve, and the position of the fifth lumbar vertebra relative to the intercrest line. Translatory shifts and vertebral tilting are also observed in these curves.

Progression of thoracolumbar curves is affected by vertebral rotation and the magnitude of the curve, and translatory shifts similar to those of lumbar curves are ob-

served. Combined curves tend to balance with age, with slightly greater progression in the lumbar component than in the initially larger thoracic component. These observations, in conjunction with our previously reported data[32] on back pain and pulmonary function, will provide additional information on the natural history of untreated adolescent idiopathic scoliosis to aid in decision-making as regards treatment.

References

1. ANDRIACCHI, THOMAS; SCHULTZ, ALBERT; BELYTSCHKO, TED; and GALANTE, JORGE: A Model for Studies of Mechanical Interactions between the Human Spine and Rib Cage. J. Biomech., **7:** 497-507, 1974.
2. CLARISSE, PHILIPPE: Prognostic évolutif des scolioses idiopathiques mineures de 10° a 29°, en période de croissance. Thesis. Université Claude Bernard, Lyon, France, 1974.
3. COBB, J. R.: Outline for the Study of Scoliosis. *In* Instructional Course Lectures, The American Academy of Orthopaedic Surgeons. Vol. 5, pp. 261-275. Ann Arbor, J. W. Edwards, 1948.
4. COLLIS, D. K., and PONSETI, I. V.: Long-Term Follow-up of Patients with Idiopathic Scoliosis Not Treated Surgically. J. Bone and Joint Surg., **51-A:** 425-445, April 1969.
5. DURIEZ, J.: Evolution de la scoliose idiopathique chez l'adulte. Acta Orthop. Belgica, **33:** 547-550, 1967.
6. FARFAN, H. F.; HUBERDEAU, R. M.; and DUBOW, H. I.: Lumbar Intervertebral Disc Degeneration. The Influence of Geometrical Features on the Pattern of Disc Degeneration — A Post Mortem Study. J. Bone and Joint Surg., **54-A:** 492-510, April 1972.
7. FARFAN, H. F.; COSSETTE, J. W.; ROBERTSON, G. H.; WELLS, R. V.; and KRAUS, H.: The Effects of Torsion on the Lumbar Intervertebral Joints. The Role of Torsion in the Production of Disc Degeneration. J. Bone and Joint Surg., **52-A:** 468-497, April 1970.
8. FARKAS, A.: Cited by Ponseti et al.[26].
9. FOWLES, J. V.; DRUMMOND, D. S.; L'ECUYER, SERGE; ROY, LOUIS; and KASSAB, M. T.: Untreated Scoliosis in the Adult. Clin. Orthop., **134:** 212-217, 1978.
10. GHOSH, P.; BUSHELL, G. R.; TAYLOR, T. K. F.; PEARCE, R. H.; and GRIMMER, B. J.: Distribution of Glycosaminoglycans across the Normal and the Scoliotic Disc. Spine, **5:** 310-317, 1980.
11. JAMES, J. I. P.: Idiopathic Scoliosis. The Prognosis, Diagnosis, and Operative Indications Related to Curve Pattern and the Age at Onset. J. Bone and Joint Surg., **36-B(1):** 36-49, 1954.
12. LANGENSKIOLD, A., and MICHELSSON, J.-E.: Experimental Progressive Scoliosis in the Rabbit. J. Bone and Joint Surg., **43-B(1):** 116-120, 1961.
13. LONSTEIN, J. E.: Prognostication in Idiopathic Scoliosis. Orthop. Trans., **5:** 22, 1981.
14. MACGIBBON, B., and FARFAN, H. F.: A Radiologic Survey of Various Configurations of the Lumbar Spine. Spine, **4:** 258-266, 1979.
15. MEHTA, M. H.: The Rib-Vertebra Angle in the Early Diagnosis between Resolving and Progressive Infantile Scoliosis. J. Bone and Joint Surg., **54-B(2):** 230-243, 1972.
16. MICHELSSON, J.-E.: The Development of Spinal Deformity in Experimental Scoliosis. Acta Orthop. Scandinavica, Supplementum 81, 1965.
17. NACHEMSON, ALF: A Long Term Follow-up Study of the Non-Treated Scoliosis. Acta Orthop. Scandinavica, **39:** 466-476, 1968.
18. NASH, C. L., JR., and MOE, J. H.: A Study of Vertebral Rotation. J. Bone and Joint Surg., **51-A:** 223-229, March 1969.
19. NILSONNE, ULF, and LUNDGREN, K.-D.: Long-Term Prognosis in Idiopathic Scoliosis. Acta Orthop. Scandinavica, **39:** 456-465, 1968.
20. PARSONS, D. B.; GLIMCHER, M. J.; and HALL, J.: Scoliosis: A Collagen Defect in the Intervertebral Disc. Orthop. Trans., **6:** 6, 1982.
21. PEDRINI, V. A.; PONSETI, I. V.; and DOHRMAN, S. C.: Glycosaminoglycans of Intervertebral Disc in Idiopathic Scoliosis. J. Lab. and Clin. Med., **82:** 938-950, 1973.
22. PEDRINI-MILLE, A.; PEDRINI, V. A.; TUDISCO, C.; PONSETI, I. V.; and WEINSTEIN, S. L.: Proteoglycans of Human Scoliotic Intervertebral Disc. Trans. Orthop. Res. Soc., **7:** 51, 1982.
23. PERDRIOLLE, RENÉ: La scoliose: son étude tridimensionnelle. Paris, Maloine, 1979.
24. PERDRIOLLE, R., and VIDAL, J.: Etude de la courbure scoliotique. Importance de l'extension et de la rotation vertébrale. Rev. chir. orthop., **67:** 25-34, 1981.
25. PONSETI, I. V., and FRIEDMAN, BARRY: Prognosis in Idiopathic Scoliosis. J. Bone and Joint Surg., **32-A:** 381-395, Jan. 1950.
26. PONSETI, I. V.; PEDRINI, V.; WYNNE-DAVIES, RUTH; and DUVAL-BEAUPERE, G.: Pathogenesis of Scoliosis. Clin. Orthop., **120:** 268-280, 1976.
27. RISSER, J. C.: The Iliac Apophysis: An Invaluable Sign in the Management of Scoliosis. Clin. Orthop., **11:** 111-119, 1958.
28. RISSER, J. C., and FERGUSON, A. B.: Scoliosis: Its Prognosis. J. Bone and Joint Surg., **18:** 667-670, July 1936.
29. ROGALA, E. J.; DRUMMOND, D. S.; and GURR, JEAN: Scoliosis: Incidence and Natural History. A Prospective Epidemiological Study. J. Bone and Joint Surg., **60-A:** 173-176, March 1978.
30. SCOTT, M. M., and PIGGOTT, H.: A Short-Term Follow-up of Patients with Mild Scoliosis. J. Bone and Joint Surg., **63-B(4):** 523-525, 1981.
31. TERVER, S.; KLEINMAN, R.; and BLECK, E. E.: Growth Landmarks and the Evolution of Scoliosis: A Review of Pertinent Studies on Their Usefulness. Devel. Med. and Child Neurol., **22:** 675-684, 1980.
32. WEINSTEIN, S. L.; ZAVALA, D. C.; and PONSETI, I. V.: Idiopathic Scoliosis. Long-Term Follow-up and Prognosis in Untreated Patients. J. Bone and Joint Surg., **63-A:** 702-712, June 1981.
33. ZALESKE, D. J.; EHRLICH, M. G.; and HALL, J. E.: Association of Glycosaminoglycan Depletion and Degradative Enzyme Activity in Scoliosis. Clin. Orthop., **148:** 177-181, 1980.
34. ZAOUSSIS, A. L., and JAMES, J. I. P.: The Iliac Apophysis and the Evolution of Curves in Scoliosis. J. Bone and Joint Surg., **40-B(3):** 442-453, 1958.