

# The SRS Classification for Adult Spinal Deformity

## Building on the King/Moe and Lenke Classification Systems

Thomas Lowe, MD,\* Sigurd H. Berven, MD,† Frank J. Schwab, MD,‡  
and Keith H. Bridwell, MD§

**Study Design.** Descriptive study of the Scoliosis Research Society (SRS) Classification for Adult Spinal Deformity using interobserver reliability measures for validation of the system.

**Objectives.** To propose and validate a classification system for adult spinal deformity that will have utility in reporting on treatment options and outcomes for affected adults.

**Summary of Background Data.** Classification systems exist for adolescent idiopathic scoliosis and have utility in categorizing spinal deformity and guiding choices for management. Adult spinal deformity is distinct from adolescent deformity. Important distinctions include present impairment and pain, regional and global decompensation, and degenerative changes within the deformity. A useful classification system for adult spinal deformity does not exist. The absence of a classification system for adult deformity compromises the ability to report on similar cases and to develop an evidence-based approach to care.

**Methods.** Descriptive study design with development of an SRS Classification System using the Delphi Method. Validation of the system using interobserver reliability measures based on responses of SRS-member surgeons to radiographic case presentations.

**Results.** Nineteen surgeons evaluated 25 cases of adult spinal deformity. Interobserver reliability for curve types ( $\kappa = 0.64$ ), regional sagittal modifiers ( $\kappa = 0.73$ ), and degenerative lumbar modifiers ( $\kappa = 0.65$ ) were substantial. Interobserver reliability was moderate ( $\kappa = 0.56$ ) for choosing a cephalad level for operative treatment and substantial for choosing a caudad level ( $\kappa = 0.77$ ).

**Conclusions.** A uniform system for classification of adult spinal deformity has significant utility in improving the ability of surgeons and authors to compare and combine similar cases, and in improving the accuracy of reports on the outcomes of care for adults with spinal deformity. The SRS Classification System for Adult Spinal Deformity has good interobserver reliability and is predictive of surgical strategies. Further validation of the SRS Classification System will include measures of intraobserver reliability, and inclusion of clinical characteristics of patient presentation and comorbidities.

**Key words:** spinal deformity, scoliosis, adult, classification. *Spine* 2006;31:S119–S125

Adult spinal deformity is a common disorder that can have a significant and measurable impact on health-related quality of life. The adult with spinal deformity presents with clinical symptoms and radiographic findings that are distinct from the adolescent with spinal deformity. Important differences between the adult and the adolescent with spinal deformity include patterns of deformity, degenerative components, the natural history of deformity progression, clinical symptoms, and presentation. The goals of operative and nonoperative care, and surgical strategies for achieving these goals of care, can differ significantly between adolescent and adult patients. Deformity in the adult spine is frequently characterized by associated degenerative changes, including spinal stenosis, spondylolisthesis, rotational subluxation, lumbar hypolordosis, and rigidity within the deformity.

Existing classification systems for scoliosis do not encompass the important considerations that are inherent in deformity in the adult spine. The Adult Spinal Deformity Committee of the Scoliosis Research Society has developed a classification for adult spinal deformity that is intended to provide an organizational structure for spinal deformity that permits comparison of similar cases, and provides a framework for an evidence-based approach to the operative and nonoperative management of deformity in the adult.

**Background.** Classification systems are important and valuable to the physician who cares for patients with spinal disorders because they serve to accurately characterize a disorder, to guide treatment and decision-making, and to form a basis for the uniform reporting of results of care that may lead to an evidence-based approach to care.<sup>1</sup> A classification system for spinal deformity has four main purposes: systematic categorization of similar disorders, prognosis regarding natural history and outcomes of care, correlation with health status or severity of deformity, and a guide for optimal care. Established classifications systems for scoliosis include nominal (diagnostic) and ordinal systems. Each established system has significant limitations in application to adult spinal deformity.

A nominal classification system for scoliosis was initially introduced by the Terminology Committee of the Scoliosis Research Society in 1969.<sup>2</sup> The classification was etiological and divided disorders of the spine into categories including idiopathic, congenital, neuromuscular, associated with neurofibromatosis, mesenchymal, traumatic, secondary to irritative phenomena, and other. A nominal classification is useful to lend insight into diagnosis and associated comorbidities. The importance of recognizing the etiology of spinal deformity is demonstrated by the disparity of previous publications on natural history and outcome in scoliosis treatment.<sup>3–5</sup> The limitations

From the \*Woodridge Orthopaedic Clinic, Wheat Ridge, CO; †University of California–San Francisco, San Francisco, CA; ‡Hospital for Joint Disease, New York University, New York, NY; and §Washington University, St Louis, MO.

The manuscript submitted does not contain information about medical device(s)/drug(s).

No funds were received in support of this work. No benefits in any form have been or will be received from a commercial party related directly or indirectly to the subject of this manuscript.

Address correspondence and reprint requests to Sigurd Berven, MD, 500 Parnassus Avenue, MU320W, San Francisco, CA 94143-0728; E-mail: Bervens@orthosurg.ucsf.edu

of a nominal system are that it provides little insight or guidance for care of specific curve types and locations.

An ordinal classification system for scoliosis is useful because it is intended to rank subtypes of deformity with recognition of specific behavior of the deformity or treatment strategies. Curve patterns are an important basis for most ordinal classification systems. These are derived from the first reported classification by Schulthess in 1905: cervicothoracic, thoracic, thoracolumbar, lumbar, and combined double primary.<sup>6</sup> An early ordinal classification for scoliosis was used by Ponsetti and Friedman in 1950 in their description of the natural history of scoliosis based on curve types.<sup>7</sup> They emphasized that specific curve types are readily recognizable and that the location of the deformity rarely changes even with growth of the curve. Their conclusions on curve type and location being important predictors of the natural history of scoliosis remain an important reason to keep curve type central to any classification system.<sup>8</sup> However, a classification system based on curve location alone has limited utility in differentiating between curve types, and in guiding strategies for care.

In 1983, King *et al* introduced an ordinal classification system for thoracic idiopathic scoliosis that was intended to provide guidance for treatment of thoracic deformity.<sup>9</sup> The authors demonstrated that the classification has significant value in determining the appropriate levels for fusion for thoracic deformities, and with the use of distraction instrumentation, the system led to a low rate of late decompensation and revision surgery. However, the classification has significant limitations, including in applicability to current segmental instrumentation systems,<sup>10</sup> applicability to patients with lumbar deformity,<sup>11</sup> and recognition of alignment and deformity in the sagittal plane.<sup>12–14</sup>

The Lenke Classification was developed by members of the Harms Study Group with the intent to be comprehensive and encompass all curve types, to be based on objective criteria for each curve type, to emphasize sagittal plane alignment, and to be easily understood and applied.<sup>15</sup> The Lenke classification provides a standardized and useful framework for determining the extent of spinal arthrodesis in deformity.<sup>16,17</sup> However, there is significant variability in the observed choice of levels by surgeons because of specific structural characteristics within the deformity, and most importantly because of considerations that are apparent from the patient's clinical presentation that "override" radiographic considerations.<sup>18</sup>

The adult with spinal deformity presents with clinical and radiographic characteristics that are distinct from the adolescent with spinal deformity. Limited work has been reported in the area of adult deformity classification. In a recent publication, a preliminary approach to lumbar adult deformities included regional and focal radiographic parameters such as lumbar lordosis,olisthesis, and endplate obliquity.<sup>18a</sup> The recognition of symptomatic degenerative changes within the deformity, including stenosis, spondylolisthesis, and rotational subluxation, is critical for an effective classification system in the adult. Similarly, global imbalance of the spine in the sagittal and coronal plane is rare in adolescent idiopathic scoliosis but has an important impact on health status and treatment options in the adult patient.<sup>19</sup> Guidance on when to do more, less, or nothing at all can be useful for the surgeon who is considering a spectrum of options and strategies for care. There is tremendous variability in the management of adult spinal deformity among physicians who care for patients with spinal deformity. While some of this is driven by the range of pathol-

ogy and complex expression of the aging spine with deformity, the presence of variability in treatment is also related to the absence of an evidence-based approach to adult deformity. The role of nonoperative care, decompression alone, limited stabilization, or long fusions has not been well defined and will remain poorly defined in the absence of a valid classification system that can be used to categorize and to report outcomes on specific presentations of adult spinal deformity. An evidence-based approach to the management of adult spinal deformity requires a valid classification as a starting point.

The purpose of this paper is to introduce a classification system for adult deformity that will have utility in accurately categorizing adults with similar disorders, and in providing a framework that will be useful in comparing treatment and outcomes between centers. The Scoliosis Research Society (SRS) Classification for Adult Deformity is intended to be used by physicians to group patients with similar radiographic presentations and to facilitate useful multicenter collaborations and comparisons of similar cases. This paper is a report of the preliminary findings and validation of the classification by members of the SRS Adult Spinal Deformity Committee.

### Development and Rationale of the SRS Adult Deformity Classification System.

An important goal of the Adult Spinal Deformity Committee of the Scoliosis Research Society is to develop a reliable, universally acceptable radiographic classification system for adult spinal deformity that would include both adult idiopathic with superimposed degenerative changes as well as adult onset "*de novo*" scoliosis. The classification is based on standing full-length radiographs in the coronal and sagittal planes.<sup>20</sup> Global balance, regional deformity patterns, and focal degenerative changes within the deformity are assessed. The classification also includes primary sagittal deformity, which is commonly related to degenerative disc disease, developmental pathology including Scheuermann's kyphosis, trauma, loss of muscle tone, and osteoporosis in older adults. The proposed classification is illustrated in Table 1.

**Major Curve Types.** Six major coronal curves types are recognized: 1) a single thoracic, 2) a double thoracic, 3) a double major, 4) a triple major, 5) a thoracolumbar, and 6) a lumbar (idiopathic or "*de novo*"). The definitions described by the Scoliosis Research Society were used to establish the major curve types.<sup>21</sup> Thoracic curves have an apex between the second thoracic vertebral body and the 11th and 12th thoracic disc. Thoracolumbar curves have an apex between the 12th thoracic vertebral body and the first lumbar vertebral body. Lumbar curves have an apex between the first and second lumbar disc and the fourth lumbar vertebral body.

Criteria for primary thoracic curves include a magnitude of 40° or more and the C7 sagittal plumbline must lie lateral to the apical vertebral body of the curve. The threshold of 40° was chosen in order to identify curves of significant magnitude to warrant consideration of extension of instrumentation and fusion. Upper thoracic curves are structural if the first thoracic rib or clavicular tilt is greater or equal to 5° or greater with the elevated side ipsilateral to the apex of the deformity. Criteria for the thoracolumbar and lumbar curves include a curve magnitude of 30° or greater and a center sacral vertical line, which passes lateral to the apical vertebral body of the curve. The lower threshold in magnitude for lumbar major curves is based on the Committee's agreement that lumbar curves of smaller

**Table 1. SRS Adult Deformity Classification**

<p><b>Primary curve types</b></p> <ul style="list-style-type: none"> <li>Single thoracic (ST)</li> <li>Double thoracic (DT)</li> <li>Double major (DM)</li> <li>Triple major (TM)</li> <li>Thoracolumbar (TL)</li> <li>Lumbar “de novo”/idiopathic (L)</li> <li>Primary sagittal plane deformity (SP)</li> </ul> <p><b>Adult spinal deformity modifiers</b></p> <p>Regional sagittal modifier (include only if outside normal range as listed)</p> <ul style="list-style-type: none"> <li>● (PT) Proximal thoracic (T2–T5): <math>\geq +20^\circ</math></li> <li>● (MT) Main thoracic (T5–T12): <math>\geq +50^\circ</math></li> <li>● (TL) Thoracolumbar (T10–L2): <math>\geq +20^\circ</math></li> <li>● (L) Lumbar (T12–S1): <math>\geq -40^\circ</math></li> </ul> <p><b>Lumbar degenerative modifier (include only if present)</b></p> <ul style="list-style-type: none"> <li>● (DDD) ↓ disc height and facet arthropathy based on x-ray include lowest involved level between L1 and S1</li> <li>● (LIS) listhesis (rotational, lateral antero, retro) <math>\geq 3</math> mm include lowest level between L1 and L5</li> <li>● (JCT) junctional L5–S1 curve <math>\geq 10^\circ</math> (intersection angle superior endplates L5 and S1)</li> </ul> <p><b>Global balance modifier (include only if imbalance present)</b></p> <ul style="list-style-type: none"> <li>● (SB) sagittal C7 plumb <math>\geq 5</math> cm anterior or posterior to sacral promontory</li> <li>● (CB) coronal C7 plumb <math>\geq 3</math> cm right or left of CSVL</li> </ul> <p><b>SRS definition of regions</b></p> <ul style="list-style-type: none"> <li>● Thoracic: apex T2–T11–T12 disc</li> <li>● Thoracolumbar: apex T12–L1</li> <li>● Lumbar: apex L1–L2 disc–L4</li> </ul> <p><b>Criteria for specific major curve types</b></p> <ol style="list-style-type: none"> <li>1. Thoracic curves <ul style="list-style-type: none"> <li>● Curve <math>\geq 40^\circ</math></li> <li>● Apical vertebral body lateral to C7 plumbline</li> <li>● T1 rib or clavicle angle <math>\geq 10^\circ</math> upper thoracic curves</li> </ul> </li> <li>2. Thoracolumbar and lumbar curves <ul style="list-style-type: none"> <li>● Curve <math>\geq 30^\circ</math></li> <li>● Apical vertebral body lateral to CSVL</li> </ul> </li> <li>3. Primary sagittal plane deformity <ul style="list-style-type: none"> <li>● No major coronal curve</li> <li>● One or more regional sagittal measurements (PT, MT, TL, L) outside normal range</li> </ul> </li> </ol>
--

magnitude than thoracic curves would be significant in clinical presentation and in surgical planning.

In addition to the six major coronal deformities, we have added a single sagittal plane deformity where there are no associated thoracic or lumbar coronal deformities that would meet the requirements of a primary coronal deformity. The criteria for a major sagittal deformity would include an increased kyphosis in one or more of the regional sagittal measurements listed under the regional sagittal modifier.

**Sagittal Modifiers.** Deformity in the sagittal plane is an important consideration in adult scoliosis. Regional kyphosis or hypolordosis has a significant impact on health status and surgical strategies for deformity correction. A regional sagittal modifier has been included to describe excessive kyphosis in each of the four regions of the spine: proximal thoracic (T2–T5), main thoracic (T5–T12), thoracolumbar (T10–L2), and lumbar (T12–S1). The regional sagittal modifier is only listed if one or more regions are outside of the proposed normal limits. A positive sagittal modifier for the proximal thoracic (PT) region would include  $\geq 20^\circ$ , for the main thoracic (MT) region  $\geq 50^\circ$ , for the thoracolumbar (TL) region  $\geq 20^\circ$ , and for the lumbar (L) region  $\geq -40^\circ$ .

**Lumbar Degenerative Modifiers.** Degenerative changes within the lumbar spine are characteristic of adult spinal defor-

mity and often are the cause of presenting clinical symptoms. A degenerative lumbar modifier was included to describe specific degenerative radiographic findings within the lumbar spine. This modifier would also only be used if there were radiographic evidence of disc narrowing, facet arthropathy, and degenerative spondylolisthesis or rotatory subluxation  $\geq 3$  mm in any plane.

**Global Balance Modifier.** The third modifier, global balance, is included to describe imbalance in either the coronal or sagittal plane. Global alignment of the spine is important in adult spinal deformity, which may be characterized by fixed sagittal and/or coronal plane imbalance. Loss of sagittal balance is significant if the C7 plumbline is  $\geq 5$  cm either anterior or posterior to the sacral promontory.<sup>19</sup> Loss of coronal balance is significant and considered in the classification if the C7 plumbline was  $\geq 3$  cm to either side of the center sacral vertical line.

## Material and Methods for Validation

**Interobserver reliability.** Radiographs from 25 cases of adult spinal deformity were used for validation of the SRS Adult Deformity Classification. Fourteen surgeons, all members of the Scoliosis Research Society, classified the deformity for each case according to the algorithm described above (Figures 1–3). Five surgeons, all members of the adult spinal deformity committee of the Scoliosis Research Society, were actively involved with the development of this system.

Preoperative posteroanterior and lateral radiographs were used for validation testing. Coronal and sagittal Cobb measurements as well as the C7 plumbline and sacral vertical line were drawn on each radiograph. The reviewers were asked to choose the primary curve type and to select all regional sagittal, degenerative lumbar, and global balance modifiers that were positive for each patient. kappa coefficients were calculated to determine interobserver reliability of the primary curve type and each of the modifiers on each set of radiographs based on reviewer responses.

Regarding a surgical strategy, the reviewers used their assessment of the classification to determine appropriate levels for instrumentation and fusion of the spine. The reviewers selected an upper instrumentation and lower instrumentation level. The interobserver reliability of the classification system to determine fusion levels was estimated by calculating the kappa coefficient values for the proposed instrumentation levels. The kappa value is the actual interobserver agreement minus that which would occur by random chance, divided by the maximum possible agreement that is not related to chance.<sup>1</sup> Thus, perfect agreement would have a kappa coefficient of 1, and random chance agreement would have a kappa coefficient of 0. A kappa value of 0.21 to 0.4 has fair agreement, 0.41 to 0.6 has moderate agreement, 0.61 to 0.8 has substantial agreement, and 0.81 to 1.0 has almost perfect agreement.<sup>22</sup>

## ■ Results

Fourteen surgeons completed evaluations for all 25 radiographic cases. Interobserver reliability of the primary curve type was kappa = 0.64. Interobserver reliability for the regional sagittal modifier was kappa = 0.73. Interobserver reliability for the degenerative lumbar mod-

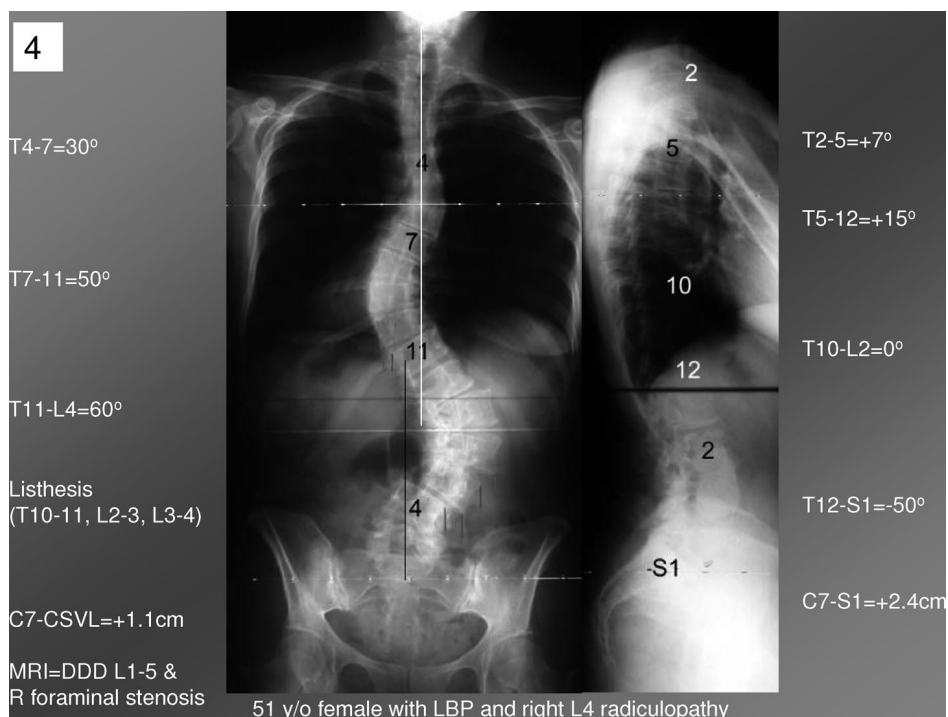


Figure 1. Case 4: Double major (DM) curve. + = lumbar degenerative modifier L2–L5; – = global balance and regional sagittal modifiers.

ifier was kappa = 0.65. Interobserver reliability for the global balance modifier was kappa = 0.92.

Regarding the selection of levels for instrumentation and fusion, there was more variability in the reviewer assessments. The interobserver reliability for the cephalad level of the construct was kappa = 0.56. The interobserver reliability for the caudad level was kappa = 0.77.

**Case Examples**

Case 1: Double major (DM) curve, + lumbar degenerative modifier L2–L5, negative global balance, and regional sagittal modifiers.

Case 2: Thoracolumbar (TL) curve, + degenerative lumbar modifier L2–L5, negative global balance, and regional sagittal modifiers.

Case 3: Double major curve, + degenerative lumbar modifier L1–L5, + MT regional sagittal modifier, and negative global balance modifier.

**Discussion**

The SRS Adult Deformity Classification offers an important framework for the establishment of a comprehensive description of adult spinal deformity. The terminol-

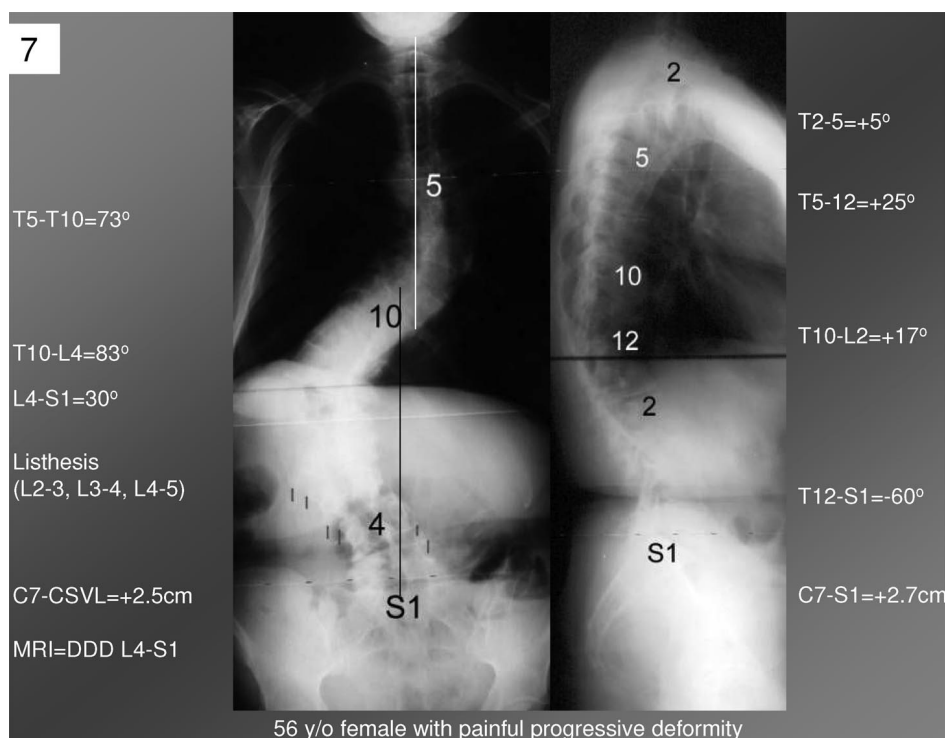
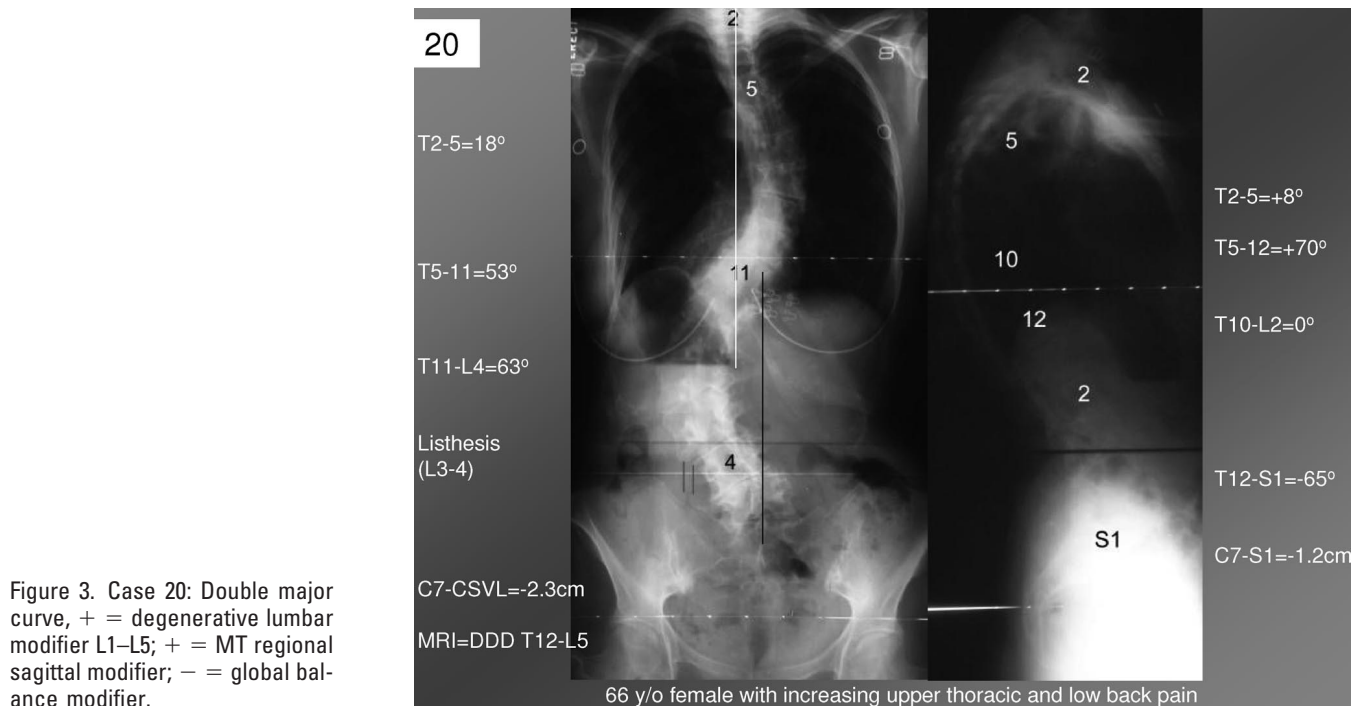


Figure 2. Case 7: Thoracolumbar (TL) curve. + = degenerative lumbar modifier L2–L5; – = global balance and regional sagittal modifiers.



ogy and definitions adopted by the SRS were applied in categorization of apical level and thus curve types. Further modifiers offer important descriptors relevant to surgical decision-making. Adult spinal deformity is distinct from adolescent deformity because of the predominance of lumbar degenerative conditions, regional loss of sagittal alignment, and global imbalance in the sagittal and coronal plane in the adult spine. Therefore, a classification that is responsive to the specific pathology of the adult spine is necessary to accurately categorize deformity and guide treatment.

The primary role of this classification system is to provide a taxonomy or framework for adult spinal deformity and to enable comparison of like cases between centers, and inclusion of like cases in multicenter studies. The fundamental requirement for a valid classification system is interobserver reliability. The interobserver reliability of other classification systems for scoliosis has been reported variably. Cummings *et al* reported poor interobserver reliability (kappa = 0.44) of the King/Moe Classification among five surgeons of variable level of training.<sup>23</sup> Similarly, Lenke *et al* reported poor interobserver reliability with kappa = 0.4 for the King/Moe classification using marked radiographs.<sup>15</sup> The Lenke Classification for adolescent idiopathic scoliosis demonstrated good and excellent interobserver reliability for curve type (kappa = 0.74–0.92) when tested by developers of the classification and independent observers.<sup>15</sup> However, subsequent reports by independent observers on marked and unmarked films demonstrated interobserver reliability in the moderate range for the Lenke classification.<sup>24,25</sup> This paper demonstrates substantial interobserver reliability for the SRS Adult Classification system. This paper is a preliminary report of the valida-

tion of the proposed system. Further work including studying the intraobserver variability, test retest reliability, and use of unmarked radiographs is required for complete validation of the system.

A secondary role of the SRS Adult Deformity Classification System is to provide guidance for optimal care, and to contribute toward an evidence-based approach to the management of adult deformity. Operative and non-operative management of adult deformity is characterized by significant variability. The reviewers of the adult deformity cases used for validation of the adult classification had substantial reliability in interobserver recommendations for a caudad fusion level (kappa = 0.77) and were within one level for a cephalad level with moderate reliability (kappa = 0.56). This level of agreement indicates that the degenerative, regional, and global modifiers that are emphasized have a positive impact on guiding decision-making and forging consensus for care. In the adolescent patient, the Lenke classification does have some utility in guiding the choice of levels for fusion and instrumentation.<sup>15,17,18,26</sup> However, decision-making in the adult extends beyond consideration of the structural curve and requires consideration of the modifiers identified. Further work including refinement and validation of the system through cases that have been treated will be required for complete validation of the system as a guide for treatment strategy and choice of fusion levels.

A limitation of the SRS Adult Deformity Classification as it is presented here is that it does not encompass important clinical considerations including presenting symptoms of the patient, age, and comorbidities including osteoporosis and systemic disease. The proposed system is designed to offer a valid radiographic classification for use in accurate and organized categorization of

adults with deformity, and to identify considerations that may guide surgical treatment. The classification may undergo further refinement in terms of clinical impact and treatment utility for operative and nonoperative patients. For example, the optimal, evidence-based treatment for a patient with a lumbar major curve and lumbar degenerative stenosis at L3–L4 with no regional or global modifiers may be quite different from the patient who presents with isolated radicular pain or from a patient who presents with pain at the apex of the deformity and curve progression. The inclusion of clinical status, pain patterns, and comorbidities in the classification system involves significantly greater complexity in data collection, and may limit the applicability of the system for use in multicenter studies or comparison between centers. Further refinement of adult deformity classifications will effectively encompass clinical correlations including presenting symptoms and comorbidities. The inclusion of clinical symptoms will significantly enhance the utility of the system as a guide to operative and nonoperative care. Future validation of the system will include reports on the variability in recommended treatment options based on classification.

Previous work has identified a correlation between health-related quality of life and radiographic parameters in the setting of adult scoliosis.<sup>18a,19,28,29</sup> Through the Spinal Deformity Study Group, database numerous parameters have emerged as independent predictors of disability and pain associated with deformity in adults. Most significantly, global sagittal imbalance, intervertebralolisthesis, and loss of lumbar lordosis are correlated with compromise of health-related quality of life measures (SRS outcomes tool, Oswestry Disability Index, MOS Short Form). Combinations of these modifiers appear to have a cumulative effect on health status. Recognition of the impact of these radiographic parameters on health status has contributed to the development of the modifiers proposed in the SRS Adult Deformity Classification. As our understanding of the disability drivers including radiographic parameters and comorbidities in adult patients grows, the classification system and its utility to the practitioner will also improve.

Spinal deformity in the adult encompasses radiographic and clinical presentations that are distinct from those characteristic of adolescent deformity. The SRS Adult Deformity Classification system is intended to provide a framework for an accurate and organized categorization of patients with spinal deformity. The classification will permit a comparison of treatment and outcomes for adults who are similarly affected by spinal deformity. The classification system was designed to encompass features of spinal deformity that are both distinct to the adult, and significant regarding health status and treatment choices. The adoption of the SRS Adult Deformity Classification will contribute significantly to our ability to accurately report treatment outcomes for adults with distinct spinal pathologies, and will contribute to the

development of an evidence-based approach for the management of adult spinal deformity.

### ■ Key Points

- Clinical presentation and treatment strategies for adult spinal deformity are different than for adolescent spinal deformity.
- A classification system for adult deformity is useful to accurately characterize adult curve patterns, to guide treatment and decision-making, and to provide a uniform basis for the development of an evidence-based approach to care.
- The SRS Classification for Adult Spinal Deformity is a reliable system for determining curve types, modifiers of the curve, and fusion levels.

### References

1. Garbuz DS, Masri BS, Esdaile J, et al. Classification systems in orthopaedics. *J Am Acad Orthop Surg* 2002;10:290–7.
2. Goldstein LA, Waugh TR. Classification and terminology of scoliosis. *Clin Orthop* 1973;93:10–22.
3. Bjure J, Nachemson A. Non-treated scoliosis. *Clin Orthop* 1973;93:44–52.
4. Nilsson U, Lundgren KD. Long-term prognosis in idiopathic scoliosis. *Acta Orthop Scand* 1968;39:456–8.
5. Collis D, Ponseti I. Long-term follow-up of patients with idiopathic scoliosis not treated surgically. *J Bone Joint Surg Am* 1969;51:425–31.
6. Schulthess W. *Die pathologie und therapie der Ruckgrats. Joachimsthal-Hand-Buch der Orthopadischen Chirurgie.* Gustav Fischer, 1905–1907.
7. Ponseti IV, Friedman B. Prognosis in idiopathic scoliosis. *J Bone Joint Surg Am* 1950;32:381–95.
8. Weinstein SL. Natural history. *Spine* 1999;24:2592–600.
9. King H, Moe J, Bradford DS, et al. The selection of fusion levels in thoracic idiopathic scoliosis. *J Bone Joint Surg Am* 1983;65:1302–13.
10. Roye DP, Farcy JP, Ricjert JB, et al. Results of spinal instrumentation of adolescent idiopathic scoliosis by King type. *Spine* 1992;17(suppl 8):270–3.
11. Lenke LG, Betz RR, Clements D, et al. Curve prevalence of a new classification of operative adolescent idiopathic scoliosis. *Spine* 2002;27:604–11.
12. Halm H, Castro WH, Jerosch J, et al. Sagittal plane correction in 'King-classified' idiopathic scoliosis patients treated with Cotrel-Dubousset instrumentation. *Acta Orthop Belg* 1995;61:294–301.
13. Cruickshank JL, Koike M, Dickson RA. Curve patterns in idiopathic scoliosis: a clinical and radiographic study. *J Bone Joint Surg Br* 1989;71:259–63.
14. Coonrad R, Murrell G, Motley G, et al. A logical coronal pattern classification of 2,000 consecutive idiopathic scoliosis cases based on the Scoliosis Research Society-defined apical vertebra. *Spine* 1998;23:1380–91.
15. Lenke LG, Betz RR, Harms J, et al. Adolescent idiopathic scoliosis: a new classification to determine extent of spinal arthrodesis. *J Bone Joint Surg Am* 2001;83:1169–81.
16. Lenke LG. Lenke Classification System of Adolescent Idiopathic Scoliosis: treatment recommendations. *AAOS Instructional Course Lectures* 2005; 54:537–42.
17. Lenke LG, Edwards CC, Bridwell KH. The Lenke Classification of Adolescent Idiopathic Scoliosis: how it organizes curve patterns as a template to perform selective fusions of the spine. *Spine* 2003;28(suppl):199–207.
18. Lenke LG, Betz RR, Hafer TR, et al. Multisurgeon assessment of surgical decision-making in adolescent idiopathic scoliosis: curve classification, operative approach, and fusion levels. *Spine* 2001;26:2347–53.
- 18a. Schwab F, Smith V, Biserni M, et al. Adolescent idiopathic scoliosis: a quantitative radiographic and clinical analysis. *Spine* 2002;27:387–92.
19. Glassman SD, Berven S, Bridwell KH, et al. Correlation of radiographic parameters and clinical symptoms in adult scoliosis. *Spine* 2005;30:682–8.
20. Horton WC, Brown CW, Bridwell KH, et al. Is there an optimal patient stance for obtaining a lateral 36° radiograph? A critical comparison of three techniques. *Spine* 2005;30:427–33.
21. Scoliosis Research Society. SRS Revised Glossary of Terms. 2002. [www.srs.org/professionals/glossary.asp](http://www.srs.org/professionals/glossary.asp).

22. Maclure M, Willett WC. Misinterpretation and misuse of the kappa statistic. *Am J Epidemiol* 1987;126:161–9.
23. Cummings RJ, Loveless EA, Campbell J, et al. Interobserver reliability and intraobserver reproducibility of the system of King et al. for the classification of adolescent idiopathic scoliosis. *J Bone Joint Surg Am* 1998;80:1107–11.
24. Ogon M, Giesinger K, Behensky H, et al. Interobserver and intraobserver reliability of Lenke's new scoliosis classification system. *Spine* 2002;27:858–63.
25. Richards BD, Sucato D, Konigsberg DE, et al. Comparison of reliability between the Lenke and King Classification systems for adolescent idiopathic scoliosis using radiographs that were not premeasured. *Spine* 2003;28:1148–57.
26. Puno RM, An KC, Puno RL, et al. Treatment recommendations for idiopathic scoliosis: an assessment of the Lenke classification. *Spine* 2003;28:2102–14.
28. Schwab F, Farcy J-P, Berven S, et al. Deformity apex, thoracolumbar alignment determine disability in adult major thoracic scoliosis: a multi-center radiographic and health status analysis. *Annual Meeting of the Scoliosis Research Society*, Buenos Aires, Argentina, September 2004.
29. Schwab F, Farcy J-P, Berven S, et al. Importance of deformity apex in Adult Lumbar Scoliosis: a multi-center radiographic and health status analysis. *Annual Meeting of the North American Spine Society*, Chicago, IL, October 2004.